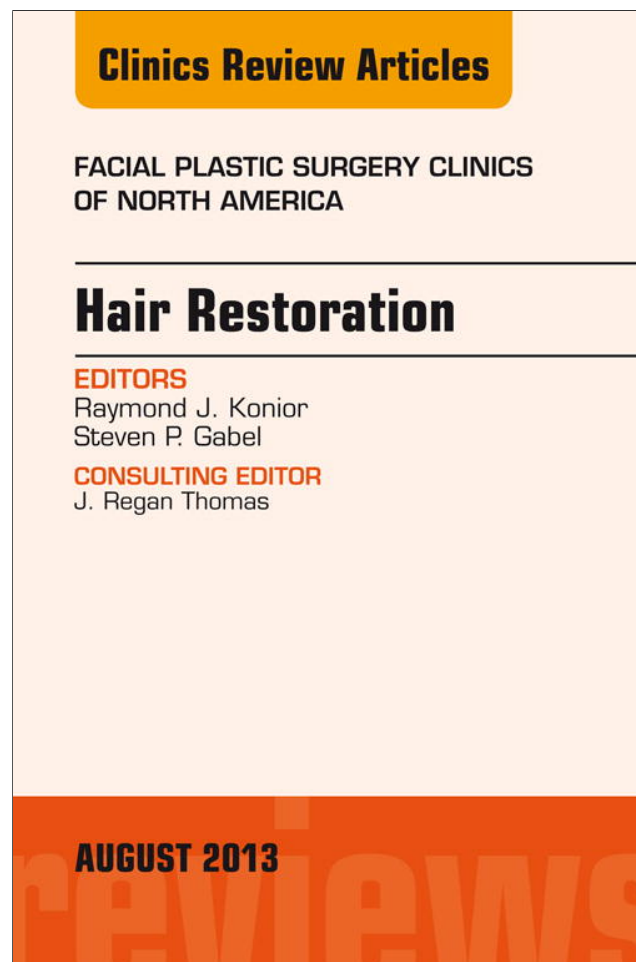

This article appeared in a journal published by Elsevier. The attached copy is furnished to the author for internal non-commercial research and education use, including for instruction at the authors institution and sharing with colleagues.

Other uses, including reproduction and distribution, or selling or licensing copies, or posting to personal, institutional or third party websites are prohibited.

In most cases authors are permitted to post their version of the article (e.g. in Word or Tex form) to their personal website or institutional repository. Authors requiring further information regarding Elsevier's archiving and manuscript policies are encouraged to visit:

<http://www.elsevier.com/authorsrights>

# Phenotype of Normal Hairline Maturation

William R. Rassman, MD<sup>a,\*</sup>, Jae P. Pak, MD<sup>a</sup>, Jino Kim, MD<sup>b</sup>

## KEYWORDS

• Phenotype • Hairline • Maturation • Facial morphology

## KEY POINTS

- Hairlines have characteristic shapes in boys and girls and change predictably as children develop into adulthood.
- The hairline in male and female children is traditionally concave in shape in all races.
- The upward movement of the female hairline leaves a widow's peak in 81% of women.
- The concave shape of the male frontal hairline transitions to a convex shape between 18-29 years of age.
- The maturing recession of the temple mounds leaves a temple peak behind in boys and girls.
- Recession of the temple mound upwards and laterally in men leaves a balding corner.
- The leading edge of hair direction in the juvenile hairline is different than the hair direction in the mature hairline in adult men and some women.

## INTRODUCTION

This article applies observational science to the process of how the hairline develops from childhood to adulthood in men and women. It also includes a summary of 1051 children from school yearbooks, aged 5 to 10 years and 15 to 18 years in boys and girls whose hairlines were not hidden by styling. It adds a missing link to the insights by Norwood and Shiell<sup>1</sup> and Hamilton<sup>2</sup> in their respective seminal articles on balding in men and women; however, this article's main focus is not about balding, but about the visual changes in the hairlines that are seen as humans age. What is seen in hairline changes results from environmental events (eg, traction alopecia), age, and hormones as they influence the genetics that code the various parts of the anatomic hairline. These genetics are evident in the phenotype of the hairline's evolution at each point in time. The available medical information on hairline evolution approaches hairline change as if it reflects a disease process or a genetic abnormality.

This article:

1. Provides physicians with a better understanding of how to educate the patient to better understand the changes seen in their hairlines
2. Will help decide whether the hairline changes are typical or not
3. Provides the physician with a more precise understanding of the genetic influences of the phenotype of hairline evolution from childhood to adulthood
4. Provides the hair restoration surgeon a foundation on which to design a hairline appropriate to meet each individual's needs, specific to their age and sex

People often ask or comment about their hairlines:

*Is my hairline receding or getting thin? Am I seeing my hairline rise? Do changes in my hairline mean that I am balding like my father or mother? I don't like the shape or position of my hairline. Is there something I can do about it?*

Disclosures: None.

<sup>a</sup> New Hair Institute, 5757 Wilshire Boulevard, Promenade #2, Los Angeles, CA 90036; <sup>b</sup> New Hair Institute, Gangnam Han-il B/D 7F, Yeoksam-dong 814-1, Korea

\* Corresponding author.

E-mail address: wrassman@newhair.com

Facial Plast Surg Clin N Am 21 (2013) 317–324

<http://dx.doi.org/10.1016/j.fsc.2013.04.001>

1064-7406/13/\$ – see front matter © 2013 Elsevier Inc. All rights reserved.

With genetic balding already affecting up to 50% of the male and female population over their lifetimes, perceptions of what is abnormal are often preprogrammed by the genetic hair loss patterns of people's parents or grandparents. An uneven or eroding hairline creates a fuzzy, ill-defined border to the face, but a full leading hairline edge makes a statement that reflects a youthful, well-framed, and healthy image; an image that many people desire.

### HAIRLINE ANALYSIS GROUP

We observed and analyzed the hairlines of 1051 adolescent and preadolescent boys and girls by analyzing school yearbooks. These measurement processes were limited by (1) hairline styles that often obscured the hairline, and (2) a single view of the subjects; these subjects were therefore omitted from the study. We supplemented these data by observing school athletic team photographs and swim teams photographs by performing Internet searches for schools all over the world, by observing children at school graduations and in recreation areas, and at social events (**Table 1**).

#### Widow's Peak and Temple Peak

It is apparent from the children studied in these yearbooks and from the multiple other observational and media sources (television, sports events, Olympic events from the 2012 Olympic Games) that male and female hairlines are similar in prepubertal children; all children start with a concave shaped hairline (ages 3–5 years). The leading central edge of the juvenile hairlines is always at the highest wrinkle of the furrowed brow. At the lateral temple borders, the forehead is narrowed in young children because of the presence of lateral temple mounds that help establish the concave shape. Widow's peaks are rare in

boys and girls between the ages of 5 and 10 years, whereas the incidence increases in teenage girls and boys. The widow's peak never extends below the highest crease of the furrowed brow (in children or adults) and, when it appears, it indicates a rising frontal hairline around it. The lateral temple mounds crowd the lateral borders of the forehead of young children, women, and some men, and there is rarely a temple peak in juvenile or female hairlines while the temple mounds are present. As the lateral temple mounds recede laterally and posteriorly, a temple peak often appears. Both the widow's peak and the temple peak are remnants of the midline juvenile hairlines and the lateral temple mound of the concave hairline.

#### Genetics, Hormones, Environment

Most prepubertal children have concave shaped hairlines. In most, there is little distinction between the hairlines of boys and girls until these children near puberty, when we believe hormone changes trigger genetic changes. These changes vary widely as children transition into adolescence and become young men and women. Although a great deal has been written about the importance of hair as a sign of health and vitality, subtle changes that show erosion of youthful hairlines greatly affect how people feel about themselves. The interplay between genetics, hormones, and possibly environmental factors (eg, traction on the hair from styling) can affect these changes.

There is little doubt that the hairlines we have studied can be influenced by traction brought on by pulling the hair back. Traction alopecia has been directly linked to hairline hair loss in African American children who have routinely worn tight braiding. This braiding has been known to produce a loss of some or all of the frontal and temple mound hair in a significant number of these children. What is unclear are the effects of the pony tail as a contributing factor affecting the evolution of what is seen in the hairlines of these girls. Considering that similar changes are seen in boys to a lesser degree, we think that styling adjuncts like the pony tail only rarely cause hairline alopecia. We were unable to distinguish the hairlines in the girls who did or did not routinely wear pony tails, and this reflects a limitation of the study and could affect the validity of some of our conclusions.

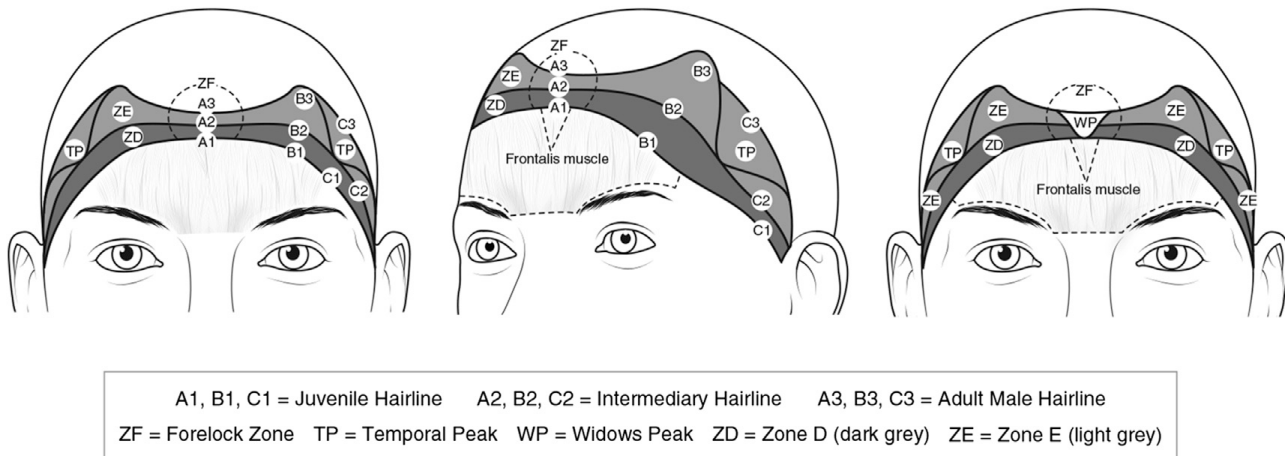
#### HAIRLINE MODEL SYSTEM

To develop language in order to define the various anatomic points of the hairline, the authors developed a modeled system, illustrated in **Fig. 1**, with the full range of hairlines. This model system can

**Table 1**  
Survey from school yearbooks in 1051 children

Sex	Age (y)	# Subjects	WP (%)	TP (%)
Boys	5	38	0	0
Boys	5–10	170	6	0
Boys	15–17	374	36	14
Boys	18	51	14	16
Girls	5	28	8	0
Girls	6–10	56	11	0
Girls	15–17	281	31	19
Girls	18	53	11	25

Abbreviations: TP, temporal peak; WP, widow's peak.



**Fig. 1.** Hairline locations.

be applied to men and women of all ages and of all races.

The border of the face is framed by the upper frontal hairline and lateral temple mounds. The anatomic location of the edges of these two structures need to be defined in order to understand the age-related standard, if there is a standard. We created a modeled system to be able to work out the changes in hairlines that we see. There are 3 critical areas that define a hairline:

1. A point where the central leading edge of the upper crease of the furrowed brow can easily be identified (point A)
2. Lateral leading edge of the upper temple hairline (point B)
3. Lateral temple mounds on the side of the forehead (point C)

The image of a face changes as a hairline recedes superiorly and laterally. As children, everyone has a hairline defined by points A1, B1, and C1 producing a hairline that is originally concave in shape (see **Fig. 1**).

## RELEVANT HAIRLINE ANATOMY

### *Frontalis Muscle*

A typical hairline cannot be understood without understanding the influence of the frontalis muscle, which lies under the forehead skin. The central, upper border of the muscle often has a small cleft in it and the skin of the forehead adheres to the muscle surface. Its edges attach to the eyebrows' deep fascia and the fascia of the upper nasal bone inferiorly. The muscle extends upward where it attaches to the galea aponeurosis, the dense fibrous tissue layer that extends across the upper part of the cranium. The superior border of the muscle is fixed and, when the muscle contracts, the eyebrows are raised. The

skin of the forehead adheres to the muscle so that, when the eyebrows are raised, the forehead develops transverse wrinkles. The lowest point of the hairline in the midline in children always touches the highest crease of the furrowed brow and this defines the medial inferior edge of a juvenile hairline.

The height of the frontalis muscle varies widely and is genetically determined. We think that there is a genetic relationship between the length of this muscle and the height of the hairline. If we are correct, people with a very short muscle will have a low hairline, whereas others with a very long muscle will have a high forehead and consequently a high hairline. Many adults with high hairlines tell me that they always had a high forehead when they present for a hairline lowering surgery. Point A1 in people with high hairlines is often located at the highest crease of the furrowed brow indicating that they always had a high hairline. On the side profile, there are lateral temple mounds that extend into the forehead, narrowing it considerably. The temple peaks, when they appear, reflect the loss of hair in Zones D and E (see **Fig. 1**).

### *Transition Zone*

The leading edge of the frontal hairline begins with a transition zone made up of vellus hairs that are shorter (a few millimeters in height), and terminal hairs that are often lighter in color, finer, and single. The vellus hairs contribute to establishing a delicate marginal leading edge. These vellus hairs do not have a sebaceous gland associated with them, but they function during sweating, acting like the fins of a radiator for reducing body heat and promoting evaporation. The short vellus hairs decrease in numbers behind the leading edge where single, finer terminal hairs begin to appear. Posterior to the leading edge, the hair appears

thicker because hairs grow in groups (follicular units) of between 2 and 5 terminal hairs each. The delicacy of the transition zone often makes it difficult to tell where the hairline starts. The wider the transition zone, the softer and more refined the hairline appears. Understanding this concept is critical for hair transplant surgeons because they must try to replicate the transition zone in all frontal hairlines.

### **Hairline Variations**

There are wide variations in the presentation of the hairline in men and women related to age, sex, and genetic inheritance. The individual characteristics of the hair influence how it looks:

1. The color of the hair on the scalp
2. The degree of coarseness of the hair
3. Whether it is curly or straight
4. The density of the hair

However, these four characteristics are unrelated to the overall shape or the position of the hairline. The hairline shape, when combined with these four hair characteristics, profoundly affects a society's view of facial beauty, something that varies significantly in different cultures.

### **HAIRLINE MATURATION DYNAMICS**

The male hairline has been well studied mainly because of the social impact of balding that starts in most men in their late teens or early 20s. This article does not address the balding patterns (behind points A3, B3, and C3) in men or women because they are discussed by Norwood and Shiell<sup>1</sup> and Hamilton.<sup>2</sup>

In his study of 360 women, Nausbaum and Fuentefria<sup>3</sup> recorded the high incidence of a widow's peak of 81% in this study group. The widow's peak is always located in zones D and E. Some balding men and women retain some or all of the hair in zones D and E, even if they are balding behind points A3, B3, and C3. This finding suggests that zones D and E have different genetic codes than the area behind these zones. The authors think that the genes in these zones may not be expressed when people bald. Genetic coding of the points anterior to A3, B3, and C3 may independently dictate a mix-and-match loss of hair in any individual. The statistical emergence of the widow's peak (8% in girls aged 5 years, 11% in girls aged 6 to 10 years, 31% in girls 15 to 17 years, and 81% of women average age 41 years) suggests that the hairlines of 81% of adult female hairlines recede posteriorly to A2 or A3 in most women as they age (see Fig. 1).

### **RECESSION PATH**

Most Caucasian men, and some women, have a distinct upward and orderly recession path from their original juvenile hairline (points A1, B1, and C1) (see Fig. 1).

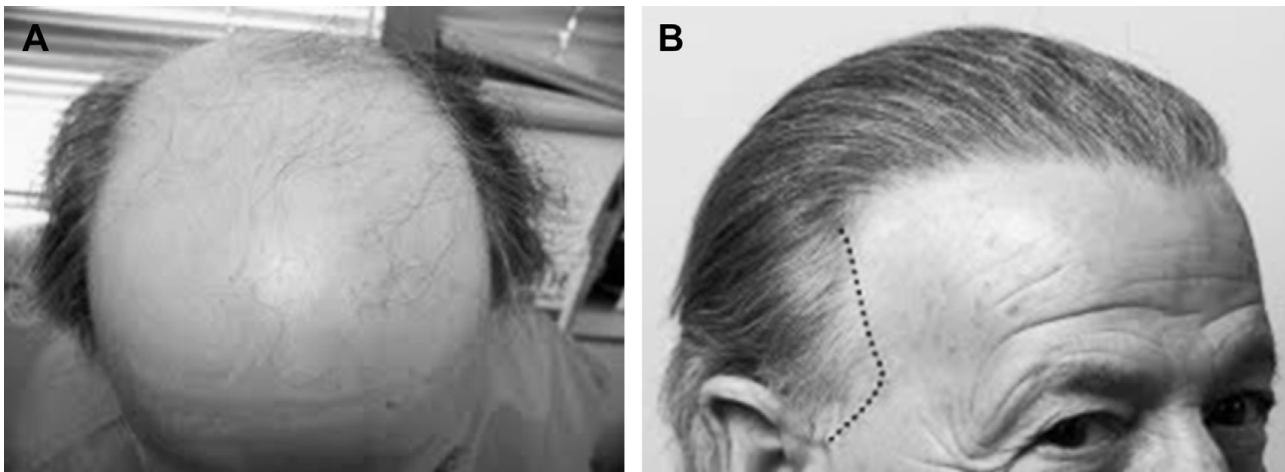
- For men, the leading edge of the central hairline recedes upward from the upper forehead crease (A1) to a distance of approximately 1.5 to 2 cm as the mature male hairline develops with the loss of hair in Zones D and E.
- The prominent temple mounds often recede laterally from point C1 in boys and young men.
- As the lateral wall of the side hairlines recedes, a temple peak often appears in both men and women, reflecting a remnant of hair in zones D and E.
- As the temple peaks become more distinct, the hair above these points often recede as well, creating a loss of hair to point B3.
- Point C1 can recede laterally to reveal a pointed temple peak at C2, which can remain into old age.

The genetic code of the temple peak is independent of the balding process common even in Norwood class 7 patterned balding men, as shown in Fig. 2. This is a Norwood class 7 pattern balding man (age 69 years) with a transplanted head of hair. Note that the temple peaks never receded. These temple peaks were never transplanted in this patient and they are often found in Norwood class 6 and 7 pattern patients. The temple peak is present (at some point in time) in most men and some women.

The hair above the lateral mounds (in zones D and E) in men becomes thinner and eventually becomes more transparent until the hair in the corners disappears to point B3. The disappearance of this hair may be rapid.

- When the hairline recedes to point B3, the convex shape of the typical mature male hairline pattern becomes evident.
- If the recession stops at points A2 and B2, a flat central hairline can remain.

In Fig. 3, Senator and vice presidential candidate Paul Ryan shows a widow's peak (a remnant of zone D) and a flat hairline showing a projection (dotted line) of where the authors think that Senator Ryan's juvenile hairline might have been. The classic mature hairlines in 90% of Caucasian men reflect a leading hairline location ranging from A2, B2, and C2 to A3, B3, and C3 in some combination. Points A, B, and C are not dependent

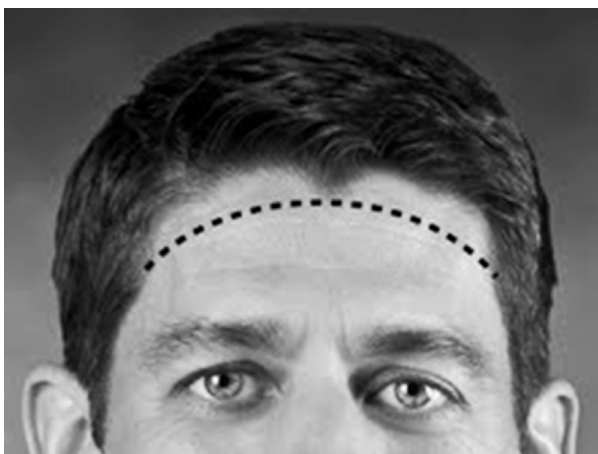

**Fig. 2.** (A) Preoperative view of 70-year-old man with a Norwood class 7 balding pattern. (B) Postoperative view with transplanted hairline. The temple peaks (*dotted line*) were not transplanted.

on one another, because one area can recede while another area may be fixed. These changes in men typically occur between the ages of 17 and 29 years and are stable providing that balding is not present. In many women, the corrugated patterns of the leading edges of their hairlines can be found in either zone D or zone E, or combinations of the two, and these remnants can make up the end-point appearance of the female hairline.

### CENTRAL FORELOCK AND WIDOWS PEAK

In some men, a strong genetically inherited central forelock exists that commonly starts at the highest crease of the furrowed brow (A1), or at times at a higher point (A2 or A3), which is resistant to the changes of the hairline around it when balding



**Fig. 3.** Official Government picture of Paul Ryan with line showing where the author thinks his juvenile hairline probably was. The lowest point on the widow's peak rests on the highest crease of his furrowed brow.

patterns develop. These forelocks vary in width and height and may extend posteriorly and laterally a considerable distance from the midline (zone F). This forelock can persist well into adulthood, and often into older age. Television host David Letterman has a moderate sized forelock that frames the face and blocks visibility of the balding pattern behind it. In balding men, these forelocks can be seen in family inheritance patterns and, as such, are a heritable trait with a distinct phenotype. Likewise, a widow's peak may remain as a heritable remnant within zone D or even as an extension of the forelock. For women, according to Nausbaum and Fuentefria,<sup>3</sup> the widow's peak is present in 81% of mature women, and varies in size (from 0.8 cm to 1.8 cm). If a line is drawn from the lowest edge of the widow's peak to the lowest border of the temple mounds in women, the location of the child's hairline can be estimated (points A1, B1, and C1); a distinctly concave hairline shape is visible (**Fig. 4**).

### Hormonal Influence on Hair Recession

Under the influence of hormones in the postadolescent male, the hairline starts a slow recession away from its youthful concave juvenile shape to a flat or convex shape, whereas the prepubertal female hairline may not change its shape to any significant degree in the same age groups. Most of the changes in male and female hairlines that occur with age do not reflect genetic balding, but rather a genetic heritable phenotypic pattern for the individual. When genetic balding does appear in men, the process does not usually start until the young men reach the age of ~17 years, and, when it appears in women, it may appear after menopause or even in women as early as their late teens and early 20s.



**Fig. 4.** A mature female hairline that shows some thinning in the temple mounds and where the hairline probably was located when she was very young (*dotted line*). The dotted line connects the tip of the widow's peak with the leading edge of the lateral mound. The suggested childhood hairline is concave.

### **Identifying Prepubertal Hairline**

The lowest part of the hairline that hugs the wrinkled brow can identify the location of the prepubertal hairline when the eyebrow is lifted and the forehead wrinkles, regardless of the presence or absence of a balding pattern. Look at yourself in the mirror and test yourself by wrinkling your brow. Do you remember the day when your hairline was located there? As the hairline matures, parts of the juvenile hairline may remain. In a small group of Caucasian men, the juvenile hairline in zone D and zone E can be retained into adulthood, even if they bald in a typical class 7 Norwood balding pattern behind points A3, B3, and C3. This tendency suggests that the genetic code for zone D and zone E is phenotypically different than the hair behind it. The poorly named widow's peak is a genetically programmed remnant of the central portion of the original concave juvenile hairline that has not receded but has taken on a distinct, recognizable pattern in zones D and E. The leading edge of the widow's peak never extends lower than the highest wrinkle of the furrowed brow.

Some men retain their juvenile hairline well into adulthood. The best example of this is former President Bill Clinton (**Fig. 5**). President Clinton's hairline is concave in shape and the authors think that this is the same hairline (less the mild erosion lateral to the midpoint) he had since childhood, suggesting that even our former President is showing some minimal signs of an aging hairline. As in all juvenile hairlines, his forehead is crowded from the sides with prominent lateral temple mounds. He has no temple peaks because he has strong temple mounds covering the area where the temple peaks



**Fig. 5.** Official Government picture of former President Bill Clinton with line showing where the author thinks his juvenile hairline probably was. A full concave hairline with strong temple mounds can be seen. In this picture, President Clinton has early recession of his frontal hairline to the sides of the midline.

would be. Other photographs of Clinton (search Google Images) show emotional moments. His forehead creases at point A1 as shown in the dotted hairline in **Fig. 5**.

### **HAIR DIRECTION**

The hair direction of the juvenile hairline hair found in zones D and E is different than the hair direction posterior to points A3 and B3. Moving laterally from the midpoint of zone D, the hair direction, which frequently points forward and parallel to the ground in the midline (above A3), gradually points more downward toward the ears. When a centrally located widow's peak remains, it may point forward or laterally depending on what direction it took in its prepubertal location in zones D and E. It is common for this widow's peak to point laterally and, when this occurs, it is often referred to as a lick. In many women whose hairline recedes to A3 and B2, remnants of hair in zones D and E can take on a minicorrugated pattern. This corrugated appearance is an important feature that should be created in a transplanted hairline if it is to look natural.

### **MINIATURIZATION**

As frontal and side hairlines erode and recede, the nonpermanent hair often undergoes miniaturization (thinning of the individual hair shafts) and, if this process is rapid, the hair may quickly disappear. The fate of miniaturized hairs seems to manifest itself clinically in 3 ways:

1. Slow progressive miniaturization, with or without moderate prolonged hair cycling (anagen/telogen cycle)

2. Hairs that remain miniaturized and do not appear to grow or cycle
3. Hairs that reach the end of their genetically determined number of growth cycles, and do not return after a given cycle (where apoptosis is the cause of the hair loss)

Miniaturization in the upper lateral corners of zone E to point B3 in women often presents with a prolonged period of miniaturization that could extend for years and, when this process occurs in men, the disappearance of the corners is usually more rapid. Miniaturized hairs in these corners appeared in many of the female athletes in the 2012 summer Olympics, possibly the result of hormone influences in athletes or traction from the pony tails worn to keep their hair away from their faces. When women lose their corners to point B3, there is a distinctly male shape to the hairline (**Fig. 6**).

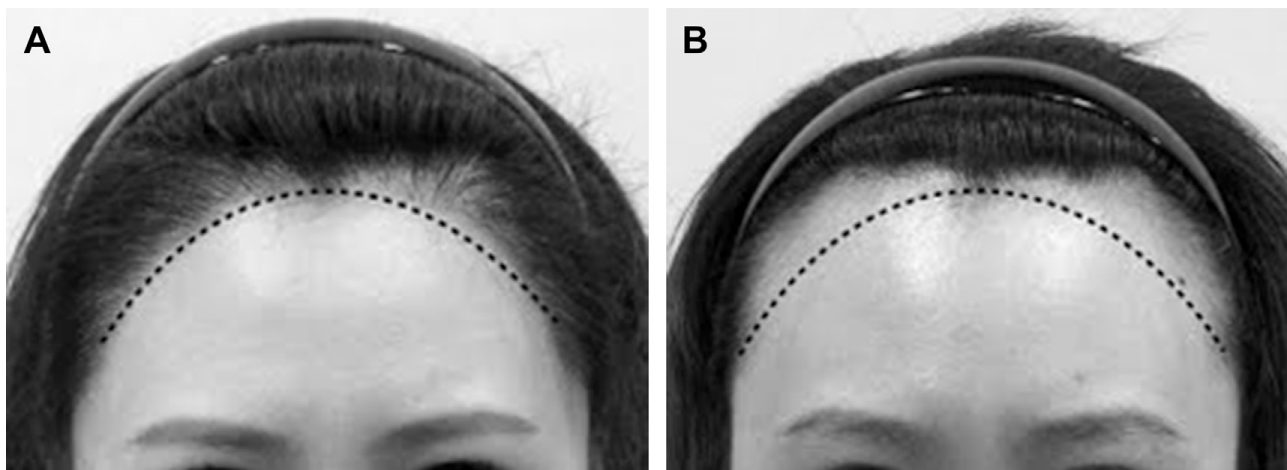
As points B1 and C1 recede, the concave shape of the child's hairline disappears. The V shape is characteristic of the mature male hairline and is the most common presentation in Caucasian men as the hair in the corners disappears. When this occurs in women, it may affect their feminine image. African and Asian men (Indian, Chinese, Korean, and Japanese) maintain the A2, B2, and C2 points more commonly than Caucasian men.

In the mature male hairline at A3, the hairs point forward and parallel to the ground, not downward to the sides, where it may have pointed had the hairs been measured at points A1 and A2 in zone D (in childhood). The distance between point A1 and point A3 is 1.5 to 2 cm. As men see the development of a mature hairline with loss of hair in zones D and E, many ask, "Is this a sign of balding?" and, "When will this recession stop?" The mature hairline in men often appears between

the ages of 17 and 29 years. The changes within zone D and zone E are genetically controlled and they are probably heavily influenced by testosterone. We do not classify miniaturization changes in zones D and E as balding, although men often look at these changes as the beginning of the balding process, particularly if there is balding in the family line.

The female hairline often remains stable for many years past puberty and well into adulthood. Significant changes in the location and shape of the temple mounds may appear with age, even before or just after puberty. The shape of the female hairline most often remains concave into adulthood. When there is lateral recession of the temple mounds, it often leaves a temple peak similar to men (point C2 and C3). In these women, the corners of the hairline in zone E to point B3 may remain full, with healthy terminal hairs. Movement of the central hairline to point A2 or A3 creates a high hairline and many women still retain points B2 and C2, even if the central hairline rises to A3. The shape of the rounded concave hairline and the crowded forehead from prominent temple mounds can be an attractive female look. If the forehead is long and significantly above the highest wrinkle of the furrowed brow, even young girls become concerned that they are losing their feminine look, or that they may be balding. Some girls have high hairlines, even before puberty, but they rarely become concerned until they are in their midteens. Hairline lowering procedures or transplants into zones D and E are good approaches to the high female hairline.

As women age, there are changes in the hairline that start to appear as early as preadolescence. These hairlines may develop slowly in the age range of 18 to 50 years. The corners (zone E to



**Fig. 6.** Female corner hairline correction. (A) Before. (B) After transplants were done. Remnants of the lateral temple mounds (temple peaks) were barely visible before surgery. The lateral temple wall was restored in this patient, incorporating remnants of the lateral temple peaks within the repair.



point B3) may start to undergo miniaturization, producing thinning in the corners, and this is a common problem for many women of all races. The terminal hair in this area can become miniaturized, changing the overall shape of the hairline from a female concave shape toward a typical male flat or convex shape as the bare corners, normally not visible in the concave hairlines with normal terminal hairs, become thin. The corner hairs may become thinner and the normal hair growth cycle may change in zone E from B2 to B3. The upper corner hair of zone E may even stop growing, which may produce a wider forehead and an upward receded frontal leading edge. These changes may reflect a variance of a mature female hairline, but I do not think that this is a normal maturing process and many women are not happy with these changes. The hairs in the corners that originally pointed downward and to the sides are the hairs that become miniaturized, which produces a flat or convex shape more typical of the male hairline. Sometimes, the central hairlines rise and the corners become miniaturized. The shape of the female hairline may follow ethnic patterns. People from India often have prominent crowding of the forehead, with strong and dominant, persistent lateral temple mounds and a low hairline. The authors assume that a low frontal hairline reflects a short frontalis muscle and a narrow forehead, which is also found in Indian men. We believe that there is no cause and effect between the low hairline and a short frontalis muscle.

The discussions on normal female hairline shapes reflect normal healthy Caucasian women who do not have the genetic effects of balding. Changes in hairline shape, the disappearance of the corner hairs secondary to miniaturization, and a recession of the frontal hairline are seen in most Caucasian women as they age. In those who have undergone facial plastic surgery, these changes are probably induced by the trauma of the cosmetic procedures.

### HAIRLINE PATTERNS: OBSERVATIONS BY THE AUTHORS

To assess the patterns described in this article, thousands of observations were made of individuals who participated in school teams (through the Internet) and viewed by observations with photographs in school yearbooks. The hairline patterns that were recognized led to the hairline schema presented in this article. We have had the opportunity to study it further, viewing the hairlines of female athletes from the 2012 Olympic

shown on television, and children at weddings, birthday parties, athletic events, and school graduations over the past 6 months. Mature women were included in our study, as well. We continued analyzing the hairlines of all women at shopping centers, airports, and conventions. It was a worthy exercise; to validate the schema presented here, which shows the wide variety of hairlines of children, men, and women of all ages. We challenged our model of female hairline evolution in thousands of individuals. The phenotype that has emerged was observed over and over again. We think that the hairline evolution model presented here will be validated by further scrutiny.

We realized that the patterns in female hairline evolution that we observed were orderly and logically reflective of what we observed clinically. Once we realized that all human hairlines developed from a common concave shape, the patterns we studied in men and women of all ages could be categorized. Combined with our extensive clinical experience, we suspected that we had discovered a process that previously was not well defined in the medical literature. The phenotype we observed can only be explained by genetic coding within the anatomic hairline outlined in **Fig. 1**. With this model, we think that we are better equipped to explain the hairline changes seen in men and women and their relationships with age. These insights will be invaluable for modern hair restoration surgeons.

### SUMMARY

This article presents phenotypic variations of the front and side hairlines found in men and women of all ages. There is a migration of the hairlines as people age, because most children start with a common concave hairline that migrates to some variant as shown in **Table 1**. The Caucasian, mature male hairline is distinct. The variations in women's hairlines show considerably more variations, at times resulting in changes as extreme as those found in the mature hairlines of normal, non-balding men.

### REFERENCES

1. Norwood OT, Shiell RC. Hair transplantation surgery. 2nd edition. Springfield (IL): Charles C Thomas; 1984. p. 5–10.
2. Hamilton JB. Patterned loss of hair in man: types and incidence. *Ann N Y Acad Sci* 1951;53:708–27.
3. Nausbaum BP, Fuentesfria S. Naturally occurring female hairline patterns. *Dermatol Surg* 2009;35:907–13.